

# Uterine Inversion in Postmenopausal Woman: A Rare Entity

Tasneem Ashraf, Samia Haroon

## ABSTRACT

Uterine inversion in old age is a rare complication. Submucosal fibroid or polyp is mostly the cause of nonpuerperal inversion. Diagnosis can be made on physical examination but it may be difficult. Management consists of manual reposition of uterus or surgery either through abdominal or vaginal route.

We report a case of nonpuerperal uterine inversion in an unmarried nulliparous postmenopausal Baloch woman having lemon size submucosal fibroid and presented with complete prolapsed inversion. Diagnosis was made clinically and confirmed at laparotomy. At laparotomy inversion was corrected first then total abdominal hysterectomy with bilateral salpingo-oophorectomy was carried out.

**Keywords:** Uterine inversion, Nonpuerperal inversion, Menopausal, Fibroid polyp, Uterovaginal prolapse.

**How to cite this article:** Ashraf T, Haroon S. Uterine Inversion in Postmenopausal Woman: A Rare Entity. J South Asian Feder Menopause Soc 2013;1(2):88-90.

**Source of support:** Nil

**Conflict of interest:** None declared

## INTRODUCTION

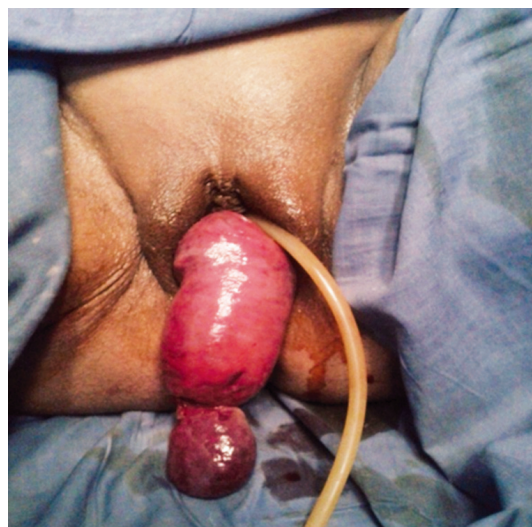Uterine inversion in the postmenopausal women is a rare problem. It usually occurs in women soon after delivery of the baby due to adherent placenta, uterine atony, prolong labor, mismanagement of third stage of labor, congenital abnormalities or weakness of uterus. According to the severity of inversion, it is graded as incomplete, complete, and prolapsed and total inversion.<sup>1</sup> Nonpuerperal uterine inversion is very rare and, according to Gomez-Lobo, only 150 cases have been reported in literature from 1887 to 2006.<sup>2</sup> Nonpuerperal inversion is usually caused by submucous myoma or other connective tissue tumors attached to the fundus of the uterus. If inversion is associated with prolapse diagnosis can be difficult on physical examination. Detail abdominal and vaginal ultrasound, laparoscopy or laparotomy may be required to confirm the diagnosis.<sup>3</sup> Management by surgical repositioning of uterus or hysterectomy is required in most of the cases.

## CASE REPORT

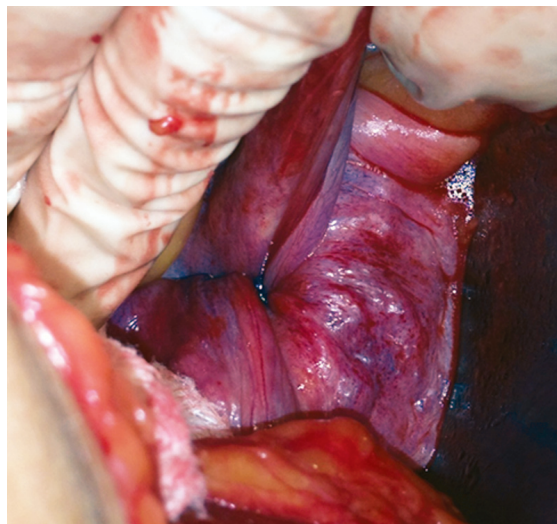
A 65 years old unmarried nulliparous Baloch lady from Nushk was presented at OPD menopausal clinic with complains of mass hanging out of vagina and profuse purulent vaginal discharge for last 1 year. There was no

history of abnormal bleeding. She also complained of chronic constipation. On physical examination, her BP was 160/90 and she was distressed due to the mass and discharge. Her pelvic examination revealed a prolapsed mass of 14 × 4 cm with a rounded solid mass of 3 × 4 cm near the apex.

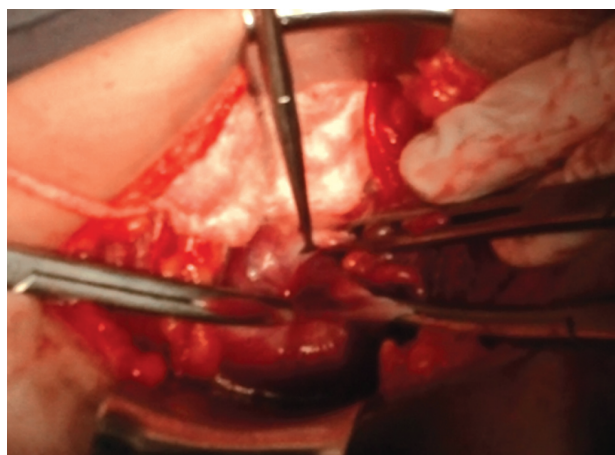
Outer surface of the mass (Figs 1 and 2) was maroon red and velvety. Uterus and cervix were not identified on bimanual pelvic examination. On investigation, she was mildly anemic. Ultrasound of abdomen and pelvis was done to confirm the diagnosis of inversion but was inconclusive. After doing her preoperative work up, laparotomy was done. Diagnosis of inversion was confirmed on laparotomy by looking at the cupping of fallopian tubes and ovaries (Fig. 2). As the cervical ring was too tight uterine repositioning was done by giving a vertical incision in the posterior portion of the ring and gentle traction on the round ligaments (Haultain's procedure) while another assistant was pushing the fundus gently up through vagina (see Fig. 3). After repositioning of the uterus it was seen that uterus was atrophic and small in size, both ovaries and fallopian tubes were congested and necrosed as a result of prolong ischemia (Fig. 4). So, her total abdominal hysterectomy along with bilateral salpingo-oophorectomy was done. Her postoperative recovery was uneventful and discharged on 6th day. Histopathology report of the specimen revealed a submucosal leiomyoma of 3 × 4 cm attached to the fundus of uterus and no malignant cells were seen on microscopic examination. She is free of complications 3 months after surgery.



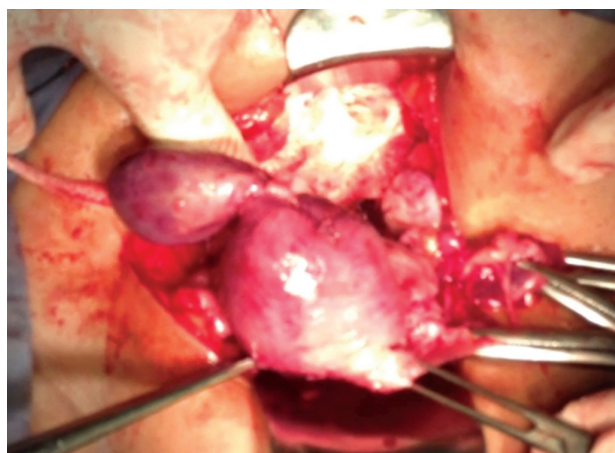
**Fig. 1:** Uterine inversion with fibroid polyp



**Fig. 2:** Cupping of fallopian tubes and ovaries



**Fig. 3:** Application of traction on the round ligaments



**Fig. 4:** Repositioning of the uterus

## DISCUSSION

Nonpuerperal uterine inversion is a rarity for the gynecologists. Puerperal uterine inversions occur as a complication of third stage of labor. While nonpuerperal

inversion is serious condition associated with polypoidal benign or malignant tumors of the uterus.<sup>4</sup> With acute inversion, patient may have severe pain in lower abdomen or excessive bleeding whereas chronic inversion may be insidious or patient may have lower abdominal discomfort, vaginal discharge, irregular vaginal bleeding or anemia.<sup>5</sup> In chronic inversion with sloughing of endometrium diagnosis, it is not very easy so detailed abdominal and vaginal ultrasound or Doppler may be required to confirm the diagnosis.<sup>6,7</sup>

As nonpuerperal uterine inversion is rarely encountered by the gynecologist thus diagnosis and management could be challenging.<sup>8</sup> In our case, on clinical examination, diagnosis was not clear so detailed ultrasound of abdomen and pelvis was done but that was also not very conclusive. Diagnosis of inversion was confirmed at laparotomy. Repositioning of uterus can be done manually in acute cases but in chronic nonpuerperal case manual reposition is not possible, especially in those cases associated with tumors. In chronic nonpuerperal cases, surgery is imperative. Considering patient's age, reproductive desire and associated conditions, surgical repositioning or hysterectomy can be done.

Surgical repositioning can be done vaginally or through abdominal route. In vaginal route approach (Spinelli's method), incision is given anteriorly in the constriction ring and bladder dissection is required; while in Kustner's method, posterior uterine wall incision is given which make it bit easier and safer.<sup>9</sup> Abdominal route repositioning can be done either using Huntington's procedure<sup>10</sup> (cup of inversion is identified, dilating the cervical ring digitally and gently pulling out round ligaments) or by Haultain's<sup>11</sup> method where a vertical incision is given in the posterior wall of the cervical ring and gentle traction is given on round ligaments. We repositioned the uterus by using Haultain's technique. Following that total abdominal hysterectomy with bilateral salpingo-oophorectomy was performed as the patient was an old menopausal lady. The other methods include laparoscopic reduction,<sup>12</sup> the use of obstetric ventouse at laparotomy<sup>13</sup> and robotically assisted laparoscopic correction.<sup>14</sup>

## CONCLUSION

Nonpuerperal uterine inversion in a postmenopausal unmarried nulliparous woman is an extremely rare event. Though, it has good prognosis but it may be very troublesome for the patient. If the gynecologists are not familiar with the condition, they can easily miss the

diagnosis so it should be always kept in mind while dealing a patient with uterine prolapse.

## REFERENCES

1. Skinner GN, Loudon KA. Nonpuerperal uterine inversion associated with an atypical leiomyoma. *Aust NZJ Obstet Gynaecol* 2001;41:100-101.
2. Gomez-Lobo V, Burch W, Khanna PC. Non-puerperal uterine inversion associated with an immature teratoma of the uterus in an adolescent. *Obstet Gynecol* 2007;110:491-493.
3. Hu CF, Lin H. Ultrasound diagnosis of complete uterine inversion in a nulliparous woman. *Acta Obstet Gynecol Scand* 2012 Mar;91(3):379-381.
4. Alumi N, Deyhar A, Gahn D, Davis G. Non-puerperal uterine inversion in a Afghan woman. *Mil Med* 2009 May;174(5):542-543.
5. Fouelifack F, Nana P, Fouedjio JH, Bechem E. Non-puerperal uterine inversion following a prolapsed leiomyoma in a Cameroonian woman. *Clinics Mother Child Health* 2011;8:1-3.
6. Krissi H, Peled Y, Efrat Z, Goldshmit C. Ultrasound diagnosis and comprehensive surgical treatment of complete non-puerperal uterine inversion. *Arch Gynecol Obstet* 2011 Mar;283:111-114.
7. Chen YL, Chen CA, Cheng WF. Submucous myoma induces uterine inversion. *Taiwan J Obstet Gynecol* 2006 Jun;45(2):159-161.
8. Omololu OM, Rabiou KA, Quadri MA, Oyedeko MO. Non-puerperal uterine inversion due to submucous fibroid: a case report. *Niger Postgrad Med J* 2011 Jun;18(2):158-160.
9. Fofie C, Baffoe P. Non-puerperal uterine inversion: a case report. *Ghana Med J* 2010;44:100-107.
10. Huntington JL. Abdominal reposition in acute inversion of the puerperal uterus. *AM J Obstet Gynaecol* 1928;15:34-40.
11. Haultain F. The treatment of chronic uterine inversion by uterine hysterectomy. *BMJ* 1901;2:974-980.
12. Rajagopalan V, Sujatha Y. Acute postpartum uterine inversion with hemorrhagic shock with laparoscopic reduction: a new method of management. *BJOG* 2006;113:1100-1102.
13. Antonelli E, Irion O, Tolck P, Morales M. Subacute uterine inversion: description of a novel replacement technique using the obstetric ventouse. *BJOG* 2006;113:846-847.
14. Zechmeister JR, Levey KA. Successful robotically assisted laparoscopic correction of chronic uterine inversion. *J Minim Invasive Gynecol* 2011 Sep-Oct;18(5):671-673.

## ABOUT THE AUTHORS

### Tasneem Ashraf

Professor and Head, Department of Gynecology (Unit IV), Bolan Medical Complex Hospital, Quetta, Pakistan; President, Society of Obstetricians and Gynaecologists of Pakistan, Pakistan

**Correspondence Address:** Room No. 5 & 6, First Floor, Saleem Medical Complex, Jinnah Road, Quetta, Pakistan, Phone: +923009381378 e-mail: ashraftasneem55@gmail.com

### Samia Haroon

Postgraduate Resident III (FCPS II), Department of Gynecology (Unit IV), Bolan Medical Complex Hospital, Quetta, Pakistan