

## CASE REPORT

# Role of Uterine Artery Embolization and Methotrexate in Cervical Pregnancy

<sup>1</sup>Keerthi Patturu Radhakrishna, <sup>2</sup>Vasanth Lakshmi, <sup>3</sup>Pushpalatha

## ABSTRACT

Cervical ectopic pregnancy in a 33-year-old gravida 8 para 1 live 1 abortion 6 following spontaneous conception at 6 weeks presented with mild vaginal spotting with no abdominal cramps. On pelvic exam, cervix slightly distended with no uterine enlargement and minimal bleeding at external orifice noted. Managed conservatively with three doses of methotrexate (MTX) and uterine artery embolization (UAE). The case is presented here for its rarity and to conclude successful conservative management is possible with MTX and UAE in treating early cervical pregnancy with mild vaginal bleeding with fetal heart allowing preservation of fertility.

**Keywords:** Cervical pregnancy, Methotrexate, Uterine artery embolization, Conservative management.

**How to cite this article:** Radhakrishna KP, Lakshmi V, Pushpalatha. Role of Uterine Artery Embolization and Methotrexate in Cervical Pregnancy. J South Asian Feder Menopause Soc 2014;2(1):35-37.

**Source of support:** Nil

**Conflict of interest:** None

## INTRODUCTION

Cervical pregnancy is a rare form of ectopic pregnancy and remains one of the most important reasons for death in early pregnancy. It has been reported to occur in 1 in 1000-95,000 pregnancies.<sup>1</sup> It represents less than 1.0% of all ectopic pregnancies and it is a well recognized complication of IVF-ET with a reported incidence of 1.8 and 13.2%.<sup>1,2</sup>

Cervical pregnancy has been attributed to several risk factors. Among these are preceding manipulation of the endocervical canal, cervical or miscarriage curettage, presence of IUD, asherman's syndrome, previous cesarean, endometritis, uterine surgery and history of diethylstilbestrol exposure.<sup>6-11</sup> A history of uterine curettage is considered to be main risk factor and can be found in up to 70% of cervical pregnancies.<sup>3-5</sup>

The most common clinical complaint is painless vaginal bleeding. It is necessary to differentiate it from cervical phase of incomplete abortion as well as bleeding cervical fibroids. Diagnosis is often made when patient is treated for evacuation of suspected spontaneous abortion. In such a circumstance, dilatation and curettage result in intractable bleeding and might necessitate an emergency hysterectomy. Routine vaginal sonography in early pregnancy avoids such adverse outcome. Magnetic resonance imaging can also be used for diagnostic purposes.<sup>1</sup>

A 33-year-old gravida 8 with cervical pregnancy has been reported here along with the emphasis on the diagnosis and discussion of its management options.

## CASE REPORT

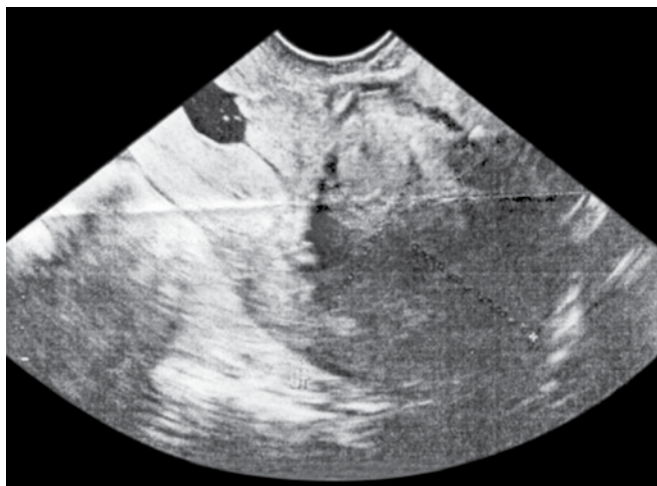
A 33-year-old woman gravida 8, para 1, live 1, abortion 6 presented to our OPD at 6 weeks with complaints of mild vaginal bleeding for past 3 days. She had all 6 previous first trimester abortions terminated by dilatation and curettage. She was evaluated for APLA, uterine anomalies and chromosomal genetic testing which were normal following her previous abortion. Her past medical history was unremarkable. On examination, her vital signs were stable and not in any acute distress. Physical examination was within normal limits. On pelvic examination, cervix felt dilated with no uterine enlargement with minimal bleeding from external os. At sonographic evaluation, gestational sac with viable fetal pole and yolk sac seen within the cervix with no gestational sac seen in the uterine cavity. Color Doppler showed vascularity in the periphery of the sac. Diagnosis was established as cervical pregnancy. Serum beta-hCG was 1,21,436 mIU/ml. Since, patient was hemodynamically stable, planned for conservative management. Three doses methotrexate (MTX) were given on alternate days as it was a early gestation. Beta-hCG were 1,181,82 mIU/ml, 33200 mIU/ml and 31000 mIU/ml after the 1st, 2nd and 3rd dose of MTX respectively. Sonography done on the next day showed absent fetal heart and collapsing sac contents. Patient vitals monitored and found to be stable but there was a slight increase in vaginal bleeding with a drop in hemoglobin by 1 gm/dl. Hence, splanned for uterine artery embolization (UAE).

Uterine artery embolization was done following informed consent about risks and complications involved with the

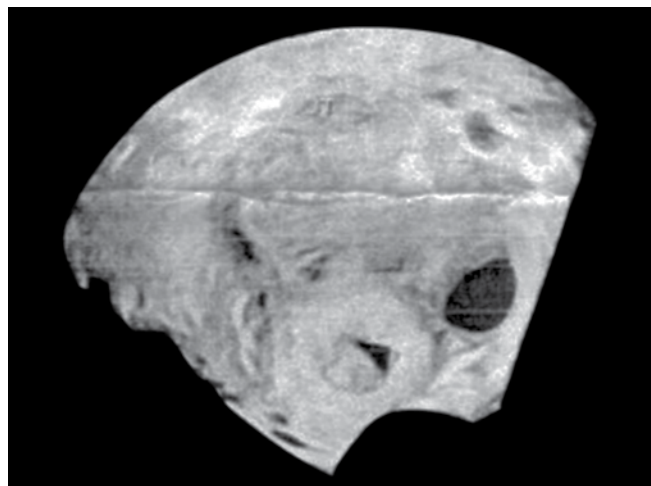
<sup>1</sup>Postgraduate, <sup>2</sup>Professor, <sup>3</sup>Professor and Chief

<sup>1-3</sup>Department of Obstetrics and Gynecology, Sri Ramachandra University, Chennai, Tamil Nadu, India

**Corresponding Author:** Keerthi Patturu Radhakrishna Postgraduate, Department of Obstetrics and Gynecology, No. 45, 33rd Cross, 11th Main Road, 4th T Main Block, Jayanagar Bengaluru 560041, Karnataka, India, Phone: 9003181023 e-mail: drkeerthipr@gmail.com



**Fig. 1:** Gestational sac within the cervical canal and empty uterine cavity



**Fig. 2:** Cervical pregnancy

procedure and the chances of massive hemorrhage with no intervention. Possibility of hysterectomy also explained to the patient. UAE was performed. Patient had no further vaginal bleeding in the postoperative period. Vitals were stable. Serial beta-hCG values were declining and were less than 15 mIU/ml in 3 weeks. Sonography done showed a sac of  $0.8 \times 1$  cm with no intrasac contents and endometrial thickness of 6.5 mm. Pelvic examination was within normal limits.

## DISCUSSION

Cervical ectopic pregnancy is a rare type of ectopic pregnancy and is potentially life-threatening because of the unexpected occurrence of uncontrollable hemorrhage from the cervix. Cervical pregnancy remains the rarest localization of inadequate implantation.<sup>3</sup> Hence, the importance of accurate and early diagnosis of cervical pregnancy has been emphasized here along with treatment options.

Sonographic criteria of cervical pregnancy are endocervical localization of gestational sac and trophoblastic invasion. A gestational sac can be visualized below the internal os, and color Doppler examination can demonstrate peritrophoblastic blood flow characteristic of early implantation. The absence of sliding sac sign which helps to distinguish cervical ectopic pregnancy from miscarriage in progress. Most patients with cervical ectopic pregnancy are women with low parity; thus, the current treatment is to preserve reproductive function. Systemic or intra-amniotic MTX administration, local intrasac KCL injections, vasopressin infiltration or vacuum evacuation of the cervical canal followed by tamponade with a Foley's catheter are some of the treatment techniques.<sup>14</sup> Local prostaglandin instillation to prevent severe hemorrhage or ligation of the uterine arteries before or after intervention may improve future fertility.<sup>12</sup> The main problem with nonsurgical management

of cervical pregnancy is the possibility of a life-threatening hemorrhage before or after pregnancy evacuation.

The successful use of UAE to obviate hysterectomy in the treatment of cervical ectopic pregnancy when fertility is desired has been reported. Any cervical ectopic pregnancy with a detectable fetal heart rate has a higher propensity for resistance to antimetabolite medication and must be regarded as a high-risk for delayed hemorrhage after UAE. UAE followed by immediate curettage may be a safe and efficient procedure for controlling serious bleeding and avoiding recurrent bleeding in cases with prolonged fetal heartbeat and high beta-hCG levels. An important advantage of using the nonsurgical treatment including UAE rather than hysterectomy for cervical ectopic pregnancy is the potential to preserve future fertility.<sup>12,13</sup>

## CONCLUSION

Uterine artery embolization along with MTX is a safe, minimally invasive, and effective procedure with a low rate of complications for cervical ectopic pregnancy with active vaginal bleeding.

## REFERENCES

1. Has R, Ermis H, Ibrahimoglu L, Yildirim A. A 22-week cervical pregnancy. *Gynecol Obstet Invest* 2000;50(2):139-141.
2. Cohen J, Mayaux MJ, Guihard-Moscato ML, Schwartz D. In vitro fertilization and embryo transfer: a collaborative study of 1163 pregnancies on the incidence and risk factors of ectopic pregnancies. *Hum Reprod* 1986 Jun;1(4):255-258.
3. Oliver R, Malik, Coker A, Morris J. Management of extratubal and rare ectopic pregnancies: case series and review of current literature. *Arch Gynaecol Obstet* 2007;276(2):125-131.
4. Parente JT, Ou CS, Levy J, Legett E. Cervical pregnancy analysis: a review and report of five cases. *Obstet Gynecol* 1983;62(1):79-82.
5. Pisarska MD, Carson SA. Incidence and risk factors for ectopic pregnancy. *Clinic Obstet Gynaecol* 1999;42(1):2-3; quiz 55-56.

6. Gun M, Mavrogiorgis M. Cervical ectopic pregnancy: a case report and literature review. *Ultrasound Obstet Gynaecol* 2002;19(3): 297-301.
7. Kraemer B, Abele H, Hahn M, Wallwiener D, Rajab TK, Hornung R. Cervical ectopic pregnancy on the portio: conservative case management and clinical review. *Fertil Steril* 2008;90(5):2011.
8. Thomas RL, Gingold BR, Gallager MW. Cervical pregnancies. A report of two cases. *J Reprod Med* 1991;36(6):459-462.
9. Spitzer D, Steiner H, Graf A, Zajc M, Staudach A. Conservative treatment of cervical pregnancy by curettage and local prostaglandin injection. *Hum Reprod* 1997;12(4):860-866.
10. Fylstra DL, Coffey MD. Treatment of cervical pregnancy with cerclage, curettage and balloon tamponade. A report of three cases. *J Reprod Med* 2001;46(1):71-74.
11. Cupr Z, Pospisil J, Milickova E. Ectopic pregnancy on the vaginal part of the uterus. *Zentralbl Gynakol* 1973;95(39):1385-1387.
12. Hirakawa M, Tajima T, Yoshimitsu K, Ishigami H, Yahata H, Wake N, Honda H. Uterine artery embolization along with the administration of methotrexate for cervical ectopic pregnancy: Technical and Clinical Outcomes [www.ajronline.org](http://www.ajronline.org).
13. Saliken JC, Normore WJ, Pattinson HA, Wood S. Embolisation of uterine arteries before termination of a 15-week cervical pregnancy. *Can Assoc Radiol J* 1994;(5):399-401.
14. Okeahialam MG, Tuffnel DJ, O'Donovan P, Sperson DA. Cervical pregnancy managed by suction evacuation and balloon tamponade. *Eur J Obstet Gynaecol Reprod Biol* 1998;79(1): 89-90.