

Primary Transitional Cell Carcinoma of Fallopian Tube in Postmenopausal Women: A Case Report and Review of Literature

¹KPK Indumathi, ²S Bhuvana, ³Jaya Vijayaraghavan

ABSTRACT

Introduction: Primary fallopian tube carcinoma is the least common gynecological malignancy encountered in practice. It accounts for about 1% of all cancers of a woman's reproductive system, and it is more commonly seen in postmenopausal women. Transitional cell carcinoma (TCC) of the fallopian tube is a rare histological variant; only around 20 cases have been reported worldwide so far. The rate of preoperative diagnosis is in the range of 0 to 10%.

Case report: A 55-year-old P3L3 previous three normal vaginal delivery, postmenopausal for 6 years, type II diabetes mellitus patient presented with complaints of bleeding per vagina and excessive watery discharge per vagina for 6 months. Complete investigations and evaluation were done. Papanicolaou smear and endometrial aspiration were normal, and showed no evidence of malignancy. Taking age into consideration with duration of symptoms for 6 months, we went ahead with total abdominal hysterectomy with bilateral salpingo-oophorectomy. Intraoperatively, right hydrosalpinx was noted. Postoperatively, histopathology revealed right TCC of fallopian tube stage Ta1 Nx M0. Patient had wound infection postoperatively and was treated with IV antibiotics. Once infection settled, patient was taken up for diagnostic laparoscopy with omental biopsy and cystoscopy with bladder wall biopsy, which showed no evidence of malignancy.

Conclusion: It is more common for other cancers to spread to the fallopian tubes rather than for cancer to begin there. This diagnosis is rarely considered preoperatively and is usually first appreciated at the time of operation or by a pathologist. If detected early, fallopian tube cancer can often be successfully treated.

Keywords: Postmenopausal, Primary fallopian tube carcinoma, Transitional cell carcinoma.

How to cite this article: Indumathi KPK, Bhuvana S, Vijayaraghavan J. Primary Transitional Cell Carcinoma of Fallopian Tube in Postmenopausal Women: A Case Report and Review of Literature. J South Asian Feder Menopause Soc 2017;5(1):58-61.

¹Junior Resident, ²Associate Professor, ³Professor

¹⁻³Department of Obstetrics and Gynecology, Sri Ramachandra University, Chennai, Tamil Nadu, India

Corresponding Author: KPK Indumathi, Junior Resident Department of Obstetrics and Gynecology, Sri Ramachandra University, Chennai, Tamil Nadu, India, Phone: +919884006300 e-mail: indu0904@gmail.com

Source of support: Nil

Conflict of interest: None

Date of submission: 01 March 2017

Date of acceptance: 05 May 2017

Date of publication: June 2017

BACKGROUND

Transitional cell carcinoma (TCC) of the fallopian tube is extremely rare. A 55-year-old postmenopausal lady with type II diabetes mellitus presented with complaints of bleeding per vagina and excessive watery discharge per vagina for 6 months. Complete investigations and evaluation were done. Papanicolaou (PAP) smear and histopathological examination of endometrial aspiration was normal, and showed no evidence of malignancy. Taking age into consideration with duration of symptoms for 6 months, we went ahead with total abdominal hysterectomy with bilateral salpingo-oophorectomy. Intraoperatively, right hydrosalpinx was noted. Postoperatively, histopathology revealed right TCC of fallopian tube stage Ta1 Nx M0. Patient had wound infection postoperatively and was treated with IV antibiotics and once infection settled, the patient was taken up for diagnostic laparoscopy with omental biopsy. Lymph node dissection was not possible due to technical difficulty of dense adhesions. Cystoscopy with bladder wall biopsy showed no evidence of malignancy.

INTRODUCTION

Primary fallopian tube carcinoma is the least common gynecological malignancy encountered in practice. It accounts for about 1% of all cancers of a woman's reproductive system, and it is more commonly seen in postmenopausal women. Transitional cell carcinoma of the fallopian tube is a rare histological variant, only around 20 cases having been reported worldwide so far. The rate of preoperative diagnosis is in the range of 0 to 10%.^{1,2}

CASE REPORT

A 55-year-old P3L3 with previous three normal vaginal deliveries, postmenopausal for 6 years, presented with complaints of bleeding per vagina and excessive watery

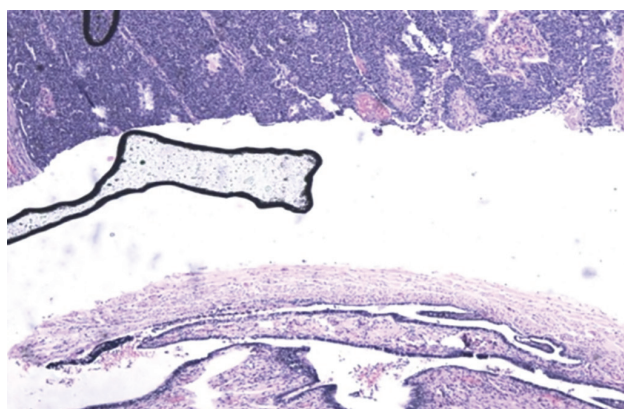


Fig. 1: Tumor with the tube

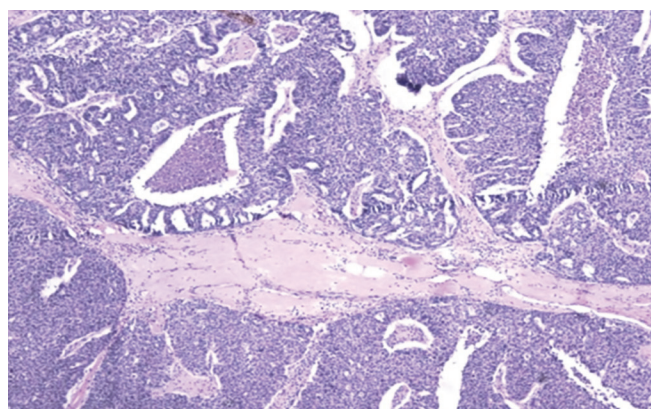


Fig. 2: Tumor

discharge per vagina for a 6-month duration. She is a known case of type II diabetes mellitus and hypertensive on treatment. There was no family history of breast or ovarian cancer. Her bladder and bowel habits were normal.

On examination, she was obese with body mass index of 37.8 with good performance status. Her vitals were stable, with no pallor, edema, or lymphadenopathy. Abdominal palpation showed no palpable mass. Per speculum examination of cervix was healthy. Vaginal examination showed bulky uterus and free fornices.

Patient was evaluated with routine blood investigations and transvaginal scan done showed thickened endometrium with small cystic spaces. The PAP smear was negative for malignancy. No endometrial tissue was obtained in endometrial aspiration; hence, it was sent for liquid-based cytology of endometrial aspirate, which showed no evidence of malignancy, and only fibrin and blood were present.

Although all investigations were normal, considering 6 years of postmenopausal bleeding without any sign of malignancy, patient was taken up for total abdominal hysterectomy with bilateral salpingo-oophorectomy. Intraoperative findings showed normal sized uterus, and cut section of uterus appeared normal. Bilateral ovaries were normal. Right hydrosalpinx was noted. Left tube was normal.

Postoperatively, on histopathology examination, right TCC of fallopian tube stage Ta1 Nx Mo was revealed.

Gross right tube measured 6.5 × 5.5 × 1.3 cm lumen occluded by gray white area.

Tumor was located in the ampulla and isthmus. Fimbria was free of tumor. Tumor size was 3.5 cm × 3 cm. Histologic type was high-grade TCC. Macroscopically, fallopian tube was partially attached to wall with no invasion. Endometrium showed proliferative pattern. Myometrium and bilateral ovaries were normal.

In the postoperative period, patient had wound infection. Wound culture showed *Enterococcus faecalis*, *Klebsiella*, and *Morganella* species, which were sensitive to amikacin,

and patient was on Inj. amikacin 500 mg OD for 5 days. Postoperative evaluation was done with computed tomography (CT) abdomen, and pelvis showed no lymph node involvement or distant metastasis and cancer antigen (CA)-125 was 70. The surgical oncologist's opinion was obtained, and it was planned according to his advice for a relaparotomy for complete staging. As the patient was not willing, and in view of recent surgery, it was decided to go for diagnostic laparoscopic staging omentectomy. Dense omental adhesions were noted on the anterior abdominal wall. The attempt to release the same resulted in oozing; hence, the procedure was abandoned. Lymphadenectomy was not done in view of dense adhesions. Intraoperatively, urologist was called in view of echymosis and increased vascularity in the dome of bladder. Cystoscopy with bladder wall biopsy and omental biopsy was taken and sent for histopathological examination. The histopathological examination report was normal (Figs 1 to 7). No evidence of malignancy was present.

Patient was referred to medical oncologist for chemotherapy, who suggested regular follow-up, and 1-year follow-up revealed no evidence of disease.

DISCUSSION

Fallopian tube carcinoma is often preoperatively misdiagnosed as ovarian carcinoma. Accurate diagnosis and

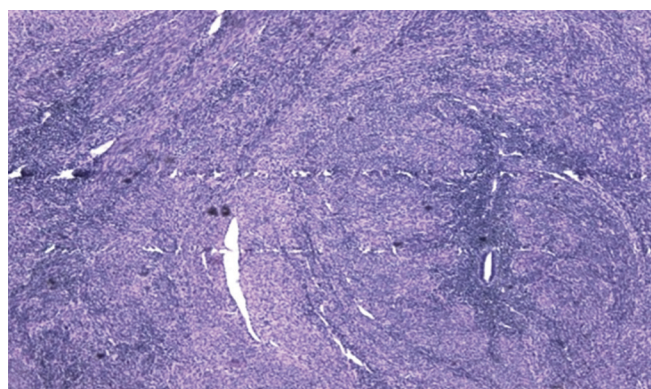


Fig. 3: Myometrium

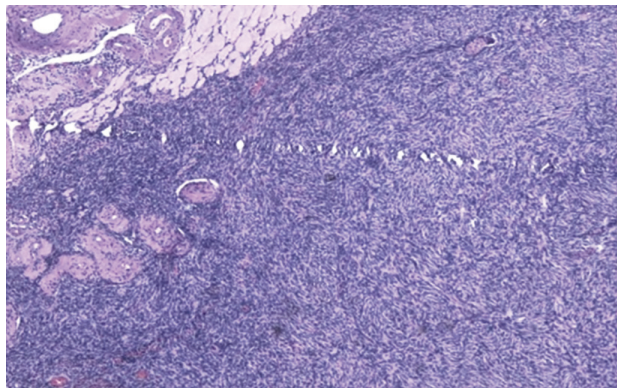


Fig. 4: Right ovary

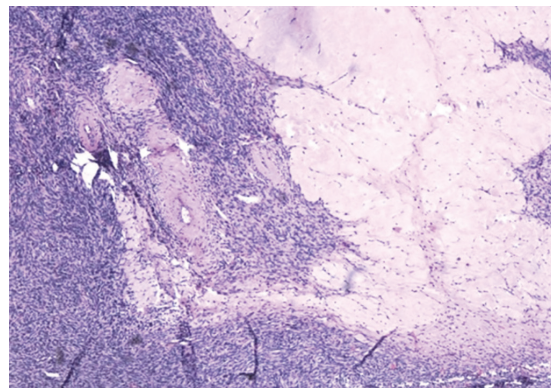


Fig. 5: Left ovary

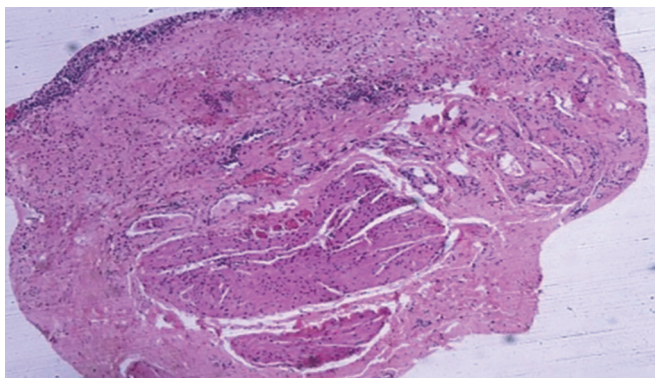


Fig. 6: Bladder

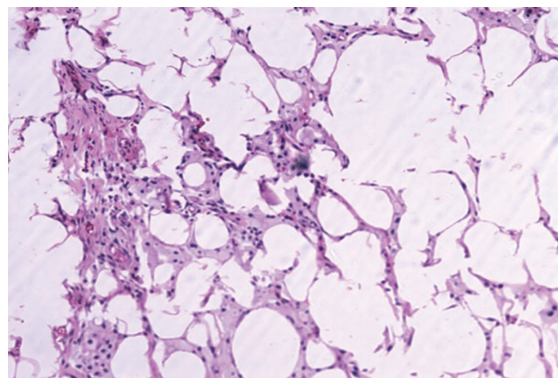


Fig. 7: Omentum

differentiation of primary fallopian tube cancer (PFTC) from lesions that have spread from the ipsilateral ovary by direct extension or from the contralateral ovary by transcoelomic route are important for monitoring trends in incidence, for better characterization of prognostic features, and possibly for improved management. Criteria for establishing the diagnosis of PFTC, first suggested by Hu et al and later modified by Sedlis³ in 1978, include all of the following:

- The tumor arises from the endosalpinx.
- The histological pattern reproduces the epithelium of the tubal mucosa.
- Transition from benign to malignant epithelium is found.
- The ovaries are either normal or with tumor smaller than that of the tube.
- The PFTC is more commonly seen in postmenopausal women, but it is not clear if the same is true about primary transitional carcinoma.

Patients with PFTC appear to have a shorter history of symptoms compared with those with epithelial ovarian cancer (EOC). About 50 to 60% of patients present with vaginal bleeding or spotting, abdominal and/or pelvic mass; and 30 to 40% of patients present with colicky or dull abdominal pain.⁴ Latzke's triad of symptoms, consisting of intermittent profuse serosanguinous vaginal

discharge, abdominal and/or pelvic pain, is reported in 15% of cases.

Between 0 and 23% of cases of PFTC may have abnormal cervical cytology suggestive of adenocarcinoma.⁴ In the present case, PAP smear and endometrial liquid-based cytology of endometrial tissue showed no evidence of malignancy. There is an isolated case report of TCC of the fallopian tube diagnosed after a total abdominal hysterectomy with salpingo-oophorectomy done for repeated PAP smear reports suggestive of squamous cell carcinoma.¹

The reported rate of preoperative diagnosis of fallopian tube carcinoma is low. Baekelandt et al⁵ have reported a preoperative diagnosis rate of 2%. In this case, both the ultrasound and the CT scan could not suggest a diagnosis of PFTC.

The pretreatment CA-125 level is an independent prognostic factor of disease-free survival and overall survival in patients with PFTC. The CA-125 is also found to be a good marker for posttreatment follow-up, similar to ovarian carcinoma.⁴

Primary adenocarcinoma constitutes more than 90% of the malignant tumors of the fallopian tube. Other less common histological types include clear cell carcinoma, squamous cell carcinoma, endometrioid carcinoma, TCC, mixed carcinoma, and sarcoma. The TCC of the fallopian

tube is a very rare histological pattern of fallopian tube carcinoma. The morphology of TCC is similar to that of tumors of the urothelium. There is a newly recognized entity known as parafallopian tube carcinoma, where the tumor is closely attached to the extraluminal portion of the tube. It is presumed to arise from Walthard's rest, paratubal cyst, or directly from the tubal serosa.⁶ Hence, it is important to distinguish primary TCC of fallopian tube from parafallopian tube TCC to identify any difference in clinical characteristics.

Surgery is the treatment of choice, as in cases of ovarian tumors. A staging laparotomy through a generous midline vertical incision is recommended, as in cases of ovarian cancer. Studies suggest that patients with PFTC have higher rates of retroperitoneal and distant nodal metastases than those with EOC.⁷ Hence, a systematic pelvic and para-aortic lymphadenectomy is preferred to selective lymph node sampling.

Patients with stage I disease without risk factors like involvement of the muscularis layer were reported to have 100% 5-year survival and need not be treated with adjuvant chemotherapy. In contrast, stage I with invasion of the muscularis layer or tumor in the fimbria and higher stages should receive adjuvant chemotherapy.^{7,8} Adjuvant chemotherapy with a combination of carboplatin and paclitaxel, which is the gold standard of chemotherapy in EOC, is now increasingly being used in PFTC.⁹ Our literature search did not reveal any report of conservative management in the form of unilateral salpingectomy or salpingo-oophorectomy for early-stage PTCC of the fallopian tube.

Uehira et al¹⁰ in a study comparing TCC-predominant PFTC with non-TCC-predominant PFTC found that TCC-predominant tumors tended to relapse later (mean, 31.2 months after diagnosis) than non-TCC-predominant tumors (mean, 14.4 months after diagnosis), resulting in a significant difference in the 2-year disease-free

survival rate. Hence, they concluded that TCC pattern and non-TCC pattern are considered to be worthy of distinction in PFTC.

CONCLUSION

The PFTC is a rare entity that poses diagnostic challenges. It is a rare tumor accounting for less than 1% of all female genital tract cancers. Histologically and clinically, it resembles epithelial ovarian carcinomas.

REFERENCES

1. Gupta N, Srinivasan R, Nijhawan R, Dhaliwal LK. Primary fallopian tube carcinoma with exfoliation of malignant cells in cervical pap smear. *Cytojournal* 2005 Feb;2:20.
2. Chin H, Matsui H, Mitsunashi A, Nagao K, Sekiya S. Primary transitional cell carcinoma of the fallopian tube: a case report and review of literature. *Gynecol Oncol* 1998 Dec;71(3):469-475.
3. Sedlis A. Carcinoma of the fallopian tube. *Surg Clin North Am* 1978 Feb;58(1):121-129.
4. Pectasides D, Pectasides E, Economopoulos T. Fallopian tube carcinoma: a review. *Oncologist* 2006 Sep;11(8):902-912.
5. Baekelandt M, Kockx M, Wesling F, Gerris J. Primary adenocarcinoma of the fallopian tube. Review of literature. *Int J Gynecol Cancer* 1993 Mar;3(2):65-71.
6. Paner GP, Gonzalez M, Al-Masri H, Smith DM, Husain AN. Parafallopian tube transitional cell carcinoma. *Gynecol Oncol* 2002 Sep;86(3):379-383.
7. Maxson WZ, Stehman FB, Ulbright TM, Sutton GP, Ehrlich CE. Primary carcinoma of the fallopian tube: evidence for activity of cisplatin combination therapy. *Gynecol Oncol* 1987 Mar;26(3):305-313.
8. Alvarado-Cabrero I, Young RH, Vamvakas EC, Scully RE. Carcinoma of the fallopian tube: a clinicopathological study of 105 cases with observations on staging and prognostic factors. *Gynecol Oncol* 1999 Mar;72(3):367-379.
9. Gemignani ML, Hensley ML, Cohen R, Venkatraman E, Saigo PE, Barakat RR. Paclitaxel-based chemotherapy in carcinoma of the fallopian tube. *Gynecol Oncol* 2001 Jan;80(1):16-20.
10. Uehira K, Hashimoto H, Tsuneyoshi M, Enjoji M. Transitional cell carcinoma pattern in primary carcinoma of the fallopian tube. *Cancer* 1993 Oct;72(8):2447-2456.