10.5005/jp-journals-10032-1108

CASE REPORT

Krukenberg Tumor from Gastric Carcinoma presented as Acute Abdomen: A Unique Presentation

[1]Aparna Jarathi, [2]Sowbarnika Ramamoorthy, [3]Jayanthi Mohan

ABSTRACT

Krukenberg tumor is an ovarian metastatic tumor from the digestive tract accounting for 10% of all ovarian malignancies. The uniqueness of this tumor is its morphology disguising as the primary tumor. We present a case of gastric carcinoma in a 36-year-old woman, who presented as acute abdomen to the emergency department. Abdominal examination revealed tender, cystic to firm mass of size 14 × 10 × 8 cm in the left lower quadrant. The abdominal ultrasonography revealed the ovarian mass of the above-mentioned size with minimal free fluid in the peritoneal cavity. An explorative laparotomy disclosed bilateral ovarian masses. Histological findings of both ovarian masses were consistent with metastatic adenocarcinoma of stomach. The survival rate of the patients can be improved by tumor-free surgery and a novel platinum-based chemotherapy. Krukenberg tumor should be considered in differential diagnosis of acute abdomen.

Keywords: Gastric carcinoma, Krukenberg tumor, Secondary ovarian tumor.

How to cite this article: Jarathi A, Ramamoorthy S, Mohan J. Krukenberg Tumor from Gastric Carcinoma presented as Acute Abdomen: A Unique Presentation. J South Asian Feder Menopause Soc 2017;5(1):66-68.

Source of support: Nil

Conflict of interest: None

Date of submission: 21 March 2017

Date of acceptance: 17 May 2017

Date of publication: June 2017

INTRODUCTION

Krukenberg tumor is a mysterious ovarian metastasis of a gastric tumor accounting for 1 to 2% of all ovarian tumors. They are characterized by their ability to occasionally reproduce mimicking the clinical and morphological appearance of primary tumors. Thus, they are a diagnostic challenge to the physician. We present a case report of a young woman who presented with acute abdomen.

[1]Assistant Professor, [2]Associate Professor, [3]Professor

[1-3]Department of Obstetrics and Gynecology, Sri Ramachandra Medical College and Research Institute, Chennai, Tamil Nadu India

Corresponding Author: Aparna Jarathi, Assistant Professor Department of Obstetrics and Gynecology, Sri Ramachandra Medical College and Research Institute, Chennai, Tamil Nadu India, e-mail: draparnaj@gmail.com

CASE REPORT

A 36-year-old parous lady presented to the emergency department with complaints of left lower quadrant abdominal pain for few hours with increasing intensity, continuous, nonradiating, and not associated with any history of vomiting or fever.

Menstrual history was normal. She had two full-term lower segment cesarean sections. Past medical and surgical history was insignificant.

On physical examination, her general condition was fair, vitals were normal; there was no pallor, icterus, and lymphadenopathy.

Breast and thyroid examination was normal. Respiratory and cardiovascular system detected no abnormality. There was a vertical midline scar with no herniation, no engorged veins or sinuses, and hernial orifices were free. On abdominal examination, a tender mass of size 12 × 10 × 8 cm cystic to firm in consistency occupying the left lumbar iliac extending into the pelvis and left hypochondriac region was found. There were no local signs of inflammation. Lower border of the mass was not felt with restricted mobility. The mass was dull on percussion. On auscultation, bowel sounds were present.

Pelvic examination revealed a mass lying in anterior, left lateral fornix, and uterus could not be made out separately. Abdominal ultrasonography showed cystic to solid mass with multiple septations in left lumbar region, giving the impression as ovarian mass (14 × 10 × 8 cm) with minimal free fluid in abdomen and left pleural effusion. Hemoglobin was 10 gm%, liver and renal function tests and other routine investigations done were normal. On explorative laparotomy, there was minimal hemoperitoneum, and hemorrhagic fluid was sent for cytology. Cystic to solid mass with bosselated appearance of size 14 × 10 × 8 cm with torsion of two turns of right ovary and hemorrhagic areas was found. Left ovary too was asymmetrically enlarged to size of 9 × 5 × 3 cm, variegated in appearance and consistency. Hence, frozen section was decided, which was inconclusive, giving torsion-related changes and tubular structures of columnar to cuboidal origin (Fig. 1). Intraoperatively,

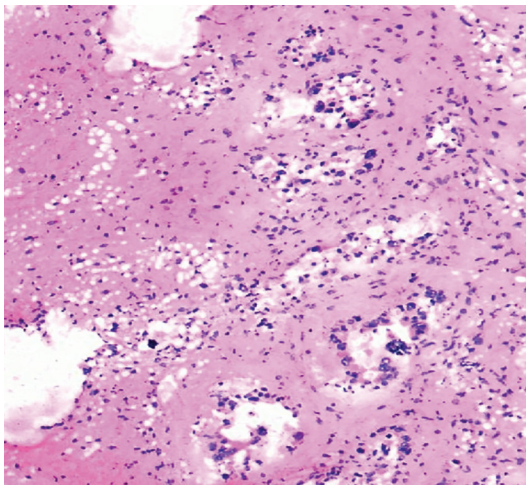

Fig. 1: Frozen section showing cuboidal to columnar cell origin

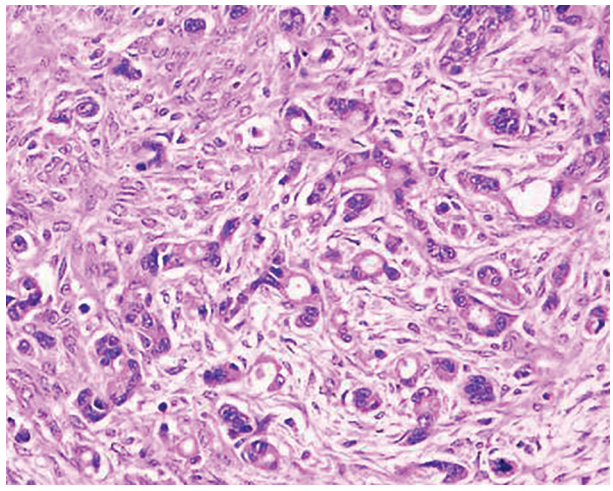

Fig. 2: Both ovaries showing signet cells of gastric origin

surgeon opinion was taken in view of suspicious frozen report for search of the primary malignancy. Both lobes of liver and its surface were normal. No peritoneal, omental deposits, or serosal invasion were detected. Infiltrative growth was felt in greater curvature of stomach. Thus, total abdominal hysterectomy with bilateral salpingo oophorectomy was planned. Upper gastrointestinal (GI) endoscopy was planned awaiting the final histopathology report. Fluid cytology came negative for malignant cells. Tumor markers, cancer antigen 125 (18.9 U/mL) and carcinoembryonic antigen (2.12 ng/mL), were normal. Histopathologic details revealed right ovarian mass of size 13 × 10 × 7 cm, weight of 150 gm, and having bosselated external surface. Cut section showed solid and cystic spaces filled with hemorrhagic fluid. Left ovary of size 9 × 5 × 3 cm and cut surface showed circumscribed yellow firm mass with focal cystic degeneration. Microscopy of right ovary revealed extensive areas of hemorrhagic infarction and interspersed tumor cells with features of metastatic adenocarcinoma. Left ovary too showed features of metastatic adenocarcinoma with intracellular mucin. Final report given was bilateral metastatic adenocarcinoma (Fig. 2). Upper GI endoscopy done after the final report showed ulceroproliferative growth in greater curvature of stomach for which biopsy was taken. Poorly differentiated adenocarcinoma with focal signet ring cell formation was the biopsy report, and, therefore, radical surgery was planned. Subtotal gastrectomy with feeding jejunostomy was done for our patient. Intraoperatively, growth in greater curvature was seen measuring 3 × 2 cm with two palpable lymph nodes. The final pathological report came as intestinal type of adenocarcinoma with focal diffuse type, poorly differentiated, and regional lymph node involvement. The specimen revealed chronic gastritis with *Helicobacter pylori* involvement (pT3 N2 C M1-G2-G3) and tumor-free margins (Fig. 3).

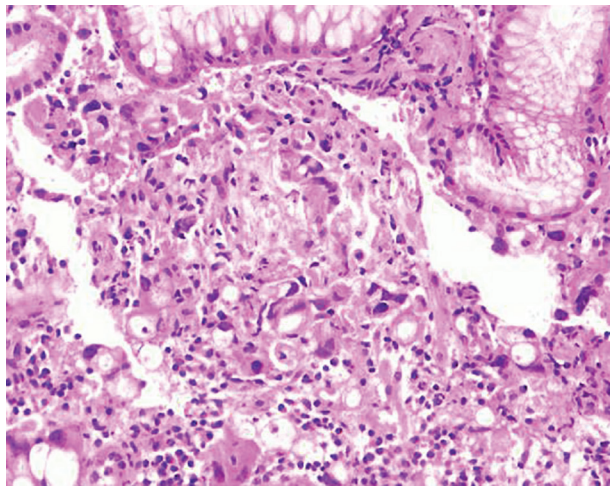

Fig. 3: Gastric specimen showing malignant signet ring cells with normal columnar cells

DISCUSSION

In 1896, Krukenberg described what he presumed was a new type of primary ovarian neoplasm.[1] The true metastatic nature of the tumor was established 6 years later. About 10% of all ovarian malignant lesions are regarded as metastatic. Of these, approximately 50% are Krukenberg tumors. The tumor is well-defined histologically and is usually secondary to a tumor in the GI tract. But, these tumors during reproductive age group are fewer as the incidence of gastric carcinoma is only 0.4 to 0.5%. Krukenberg tumors tend to be in younger age group with median age of 45 years.[2] Most common presenting symptoms are abdominal pain and distension in relation to the ovarian involvement. Bilateral in more than 80% of the reported cases, the ovaries are asymmetrically enlarged, with a bosselated contour. Sectioned surfaces are yellow or white; they are usually solid, although they are occasionally cystic as in our case. Route of metastasis is through three possible paths. Lymphatic is the most common route with vascular as

well as peritoneal invasion. This is evident as ovarian metastasis is seen in early gastric cancers due to rich lymphatic plexus of gastric mucosa and submucosa. Surface implants too are given as another route in few studies. Premenopausal ovary is more receptive, as it is richly supplied with vessels and lymphatic plexus. Hence, we see Krukenberg tumors in younger age group compared with the other malignant ovarian lesions. Frozen section diagnosis is a reliable method with good sensitivity and higher specificity for the surgical management of patients with an ovarian mass.[3] Immunohistochemistry is helpful in distinguishing the primary and metastatic ovarian carcinoma. Thus, pathological diagnosis forms an essential part in secondary ovarian tumors. Prognosis of the tumor is poor. Median survival rate is 14 months. Prognosis is poor when the primary tumor is identified after the ovarian metastasis is discovered. It is much lower in gastric than with breast and colorectal carcinoma. Absence of residual disease and limited disease extent are favorable factors for metachronous tumors of gastric origin, not the age, size, and stage of gastric adenocarcinoma after the ovarian metastasis.[4] The role of tumor-free surgery and platinum-based chemotherapy is reasonable to improve the survival of these patients.[5,6] Our patient has received totally six cycles of chemotherapy until now. The first two cycles were cisplatin. Other four cycles were paclitaxel with cisplatin given every 3 weeks. She is with oncology follow-up and faring better.

CONCLUSION

Krukenberg tumor should be considered in differential diagnosis of acute abdomen, though it is very rare. Awareness of unusual presentation helps prevent incorrect diagnosis.

REFERENCES

1. Haakonsen M, Gudmundsen TE, Lilleng R. Krukenberg tumor. A seldom considered condition?. Tidsskr Nor Laegeforen 1997 Jun;117(15):2180-2181.
2. Al-Agha OM, Nicastri AD. An in-depth look at Krukenberg tumor: an overview. Arch Pathol Lab Med 2006 Nov;130(11): 1725-1730.
3. Ghaemmaghami F, Fakour F, Karimi Zarchi M, Behtash N, Modares Gilani M, Mousavi A, Shariat M. Clinical assessment, gross examination, frozen section of ovarian masses: do patients benefit? Arch Gynecol Obstet 2008 Sep;278(3):209-213.
4. Kim HK, Heo DS, Bang YJ, Kim NK. Prognostic factors of Krukenberg's tumor. Gynecol Oncol 2001 Jul;82(1):105-109.
5. Sandmeier D, Lobrinus JA, Vial Y, Delaloye JF, Genton CY. Bilateral Krukenberg tumor of the ovary during pregnancy. Eur J Gynaecol Oncol 2000;21(1):58-60.
6. Cosme A, Ojeda E, Bujanda L, Torrado J, Barrio J. Krukenberg tumor secondary to gastric carcinoma in a woman in her eighth month of pregnancy. Gastroenterol Hepatol 2001 Feb;24(2):63-65.